

FIG 1:- Echocardiography Report before homoeopathic care.

www.bhadrahomeo.com



Manipal Heart Foundation
INSPIRED BY LIFE

ECHOCARDIOGRAPHY REPORT

Name : MRS.
Referred No :
Lab.No :
Referred by : Dr. REFERRED

Sex : Female Age : 34 Year(s)
Bill No. : CS1841847
Date of Receipt 02 Nov 2006 09:15
Date of Report: 02 Nov 2006 10:03
Location : RP;
Order No :1371734

DIMENSIONS

M - MODE MEASUREMENTS TEST VALUES

	TEST VALUES	NORMAL VALUES
AO :	24	20 - 37 MM
LA :	30	24 - 40 MM
LVIDd :	34	37 - 53 MM
LVIDS :	23	24 - 36 MM
IVSd :	13	6 - 12 MM
LVPWd :	13	6 - 12 MM
EF :	62	>50 %
FS :	33	
RVIDd :		6 - 23 MM
AO(Root):		
LVEDV :		
ESV :		

VALVES

Mitral Valve	NORMAL
Tricuspid Valve	NORMAL
Aortic Valve	BICUSPID AND THICKENED
Pulmonary Valve	NORMAL

CHAMBERS

Left Atrium	NORMAL
Right Atrium	NORMAL
Left Ventricle	CONCENTRIC LVH
Right Ventricle	NORMAL

SEPT

IVS	INTACT
IAS	INTACT

Contd2

First Indian multi-superspecialty hospital, ISO 9001-2000 certified for Clinical, Nursing, Diagnostics and allied areas

Airport Road, Bangalore 560 017, India. Phone : 91 80 2528 7742/43/45/46/48 - 51. Fax : 91 80 2528 7741.
www.manipalhospital.com

FIG 1:- Echocardiography Report before homoeopathic care.

www.bhadrahomeo.com

Great Vessels	
Aorta	NORMAL
Pulmonary Artery	NORMAL
PERICARDIUM	NORMAL
DOPPLER DATA	
Mitral Valve	NORMAL
Aortic Valve	GRD ACROSS AV: 51/26mmHg
Tricuspid Valve	NORMAL
Pulmonary Valve	NORMAL
WALL MOTION ANALYSIS	NO REGIONAL WALL MOTION ABNORMALITY
CLOTS / VEGETATIONS	NIL
FINAL DIAGNOSIS	BICUSPID AND THICKENED AORTIC VALVE MILD AORTIC STENOSIS CONCENTRIC LV HYPERTROPHY NO REGIONAL WALL MOTION ABNORMALITIES NORMAL LV SYSTOLIC FUNCTION.
Dr.MAHANTESH.R.CHARANTIMATH Consultant Cardiologist	<i>Sivagami</i> TECHNICIAN

FIG 1:- Echocardiography Report before homoeopathic care.

www.bhadrahomeo.com

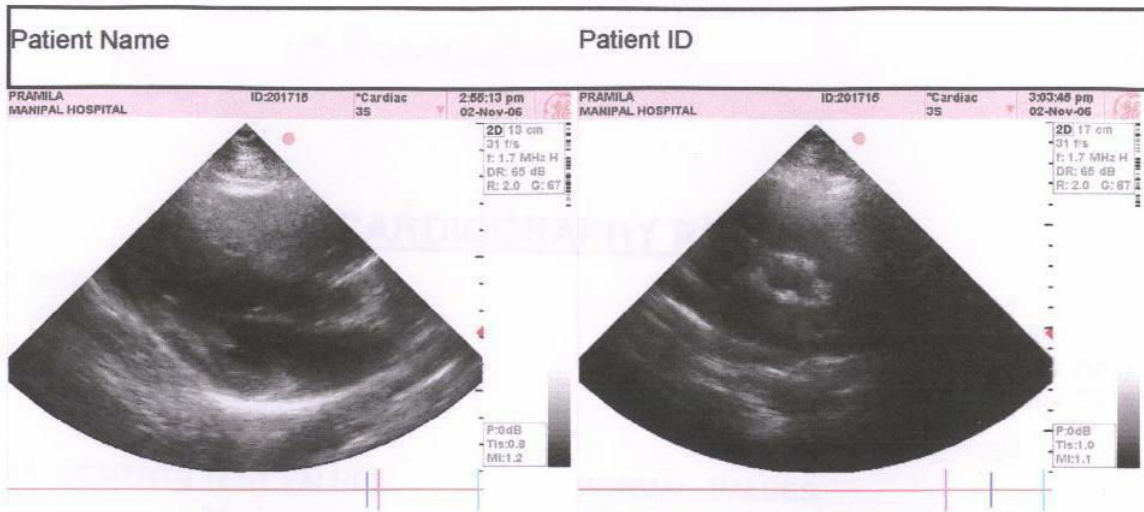


Image 1

Image 2

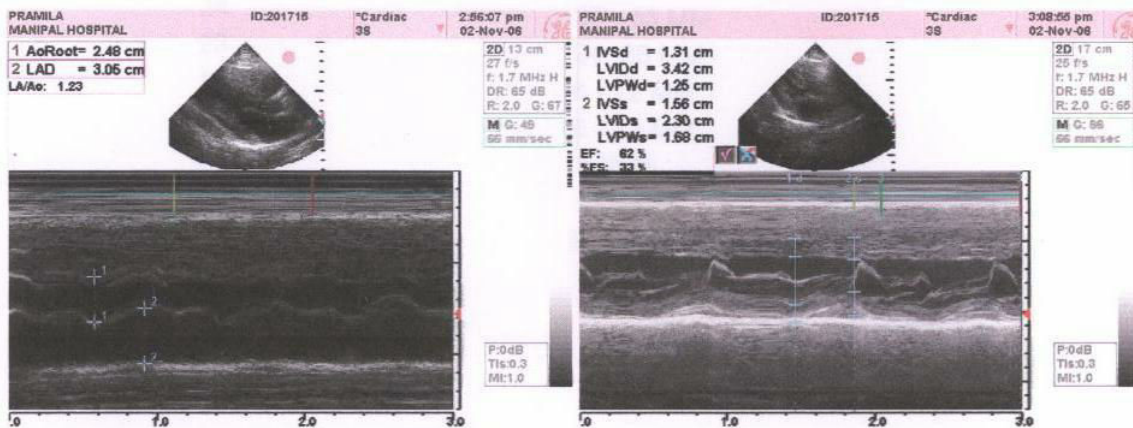


Image 3

Image 4

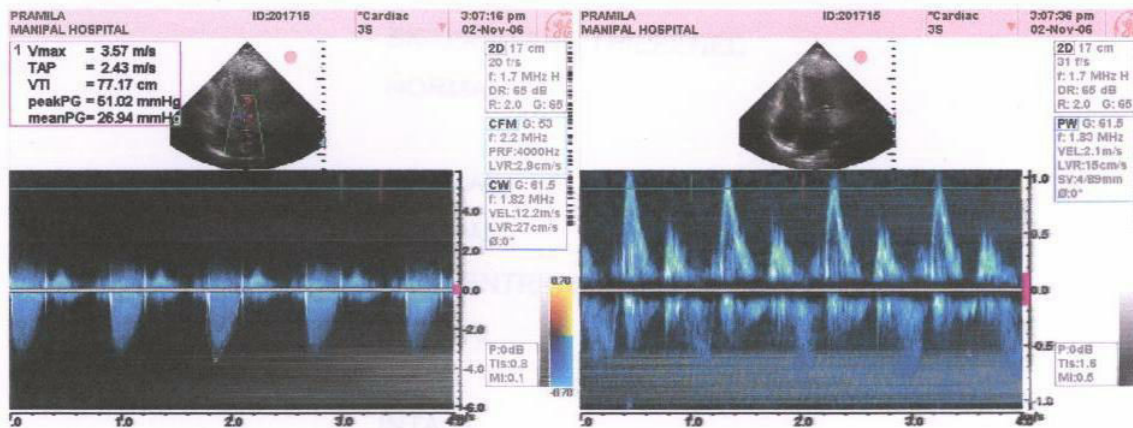


Image 5

Image 6